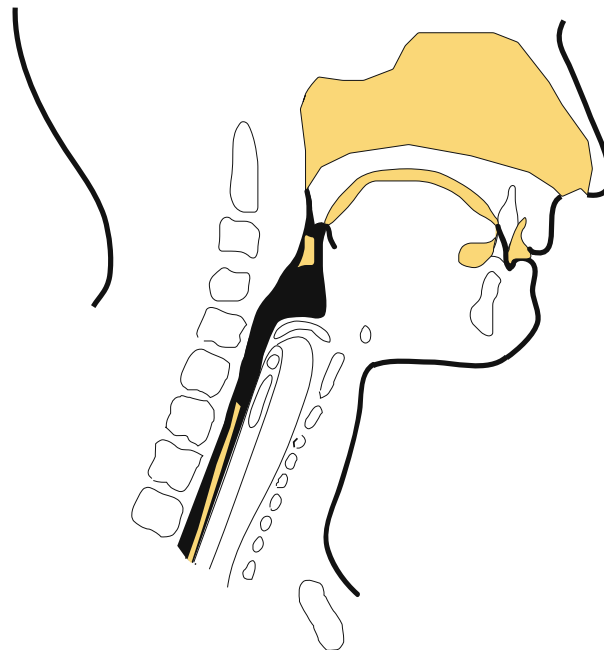


Swallowing Disorders

Swallowing is one of the most complex neuromuscular interactions in the human body (American Speech Language Hearing Association, 2004). It involves the skilled coordination of nerves and 50 different pairs of muscles in the face, neck, and esophagus (National Institute on Deafness and Other Communication Disorders, 1988). Individuals who have sustained an acquired brain injury (ABI) are at high risk for swallowing disorders, known as dysphagia, due to the diffuse nature of the lesion(s), damage to cranial nerves, and/or damage occurring to the central nervous system. The incidence of swallowing problems following a traumatic brain injury (TBI) is generally pervasive throughout the early stages of recovery. Likewise, it is also not uncommon to find significant residual problems requiring long-term therapeutic intervention. Studies have reported an incidence rate as high as 80% with 16% of those individuals still needing assistance for eating one-year post injury (Duong, Englander, Wright, Cifu, Greenwald, & Brown, 2004). This article is intended to provide an abbreviated overview of the complex issues related to swallowing disorders in individuals who have sustained an ABI, and specifically concepts related to anatomy and physiology, complications, and warning signs.

A normal swallow has three basic phases: Oral (includes oral preparatory functions), pharyngeal, and esophageal. The oral phase includes both automatic reflexes and voluntary movements and involves the delivery of food to the mouth, mastication (chewing) with bolus formation (a soft mass of chewed food), and movement of the bolus towards the back of the throat (pharynx). Pressure from the bolus stimulates the pharyngeal trigger mechanism beginning the pharyngeal phase (Logeman, p.29). The entire sequence lasts about one second (Spieker, 2000). Common disorders in the oral phase include: abnormal muscle tone and/or sensation, abnormal/primitive reflexes, difficulty chewing food, forming a bolus, controlling the food bolus and propelling it to the back of the mouth.

The pharyngeal phase is reflexive, complex, and the shortest of the phases. It begins with sensory input from the oral cavity and the pharynx that initiates elevation and forward movement of the larynx. The epiglottis moves downward to cover the airway, while additional muscles trigger to close off the nose and to propel the food through the throat. The time taken for the bolus to move from the point when the pharyngeal swallow is triggered



to the esophagus is normally one second or less (Logeman, p.35). The pharyngeal trigger activates twenty-nine muscle pairs during this process (Kelly & Buchholz, 1996). Common disorders in the pharyngeal phase include: delayed or absent trigger of the swallow, nasal regurgitation, poor coordination of the airway protection valves, and decreased tongue base retraction.

The pharyngeal phase is followed by the esophageal phase in which the bolus is propelled about 25 cm through the esophagus to the opening of the stomach. The esophageal phase is involuntary, resulting from peristalsis and gravity, and may take up to 20 seconds (Spieker, 2000). Common disorders in the esophageal phase include: motility disorders, mechanical obstructions, and complaints of food sticking in the throat or chest.

Disruption to any of the three phases of the normal swallow (oral, pharyngeal or esophageal) is serious and can be life threatening. Complications arise when food or liquid spills, penetrating the entrance of the airway, and is aspirated into the trachea and into the lungs. Aspiration pneumonia may develop due to the presence of foreign material in the lungs. Aspiration may occur silently and does so in about half of persons with dysphagia; thereby the signs are not detected until symptoms of pneumonia are observed (Agency for Health Care Policy and Research, 1999). In addition to leaking or spilling food/liquid into the airway, food particles left behind in the mouth between the teeth and facial musculature or in spaces within the pharynx can lead to aspiration. The food may become dislodged and

Swallowing Disorders *continued*

penetrate the airway and be aspirated. Esophageal complications may include the development of a pocket outside the esophagus caused by weakness in the esophageal wall. The abnormal pocket traps food being swallowed. While lying down or sleeping, the undigested food may be drawn back up into the pharynx. The esophagus may also be too narrow, causing food to stick and preventing other foods or liquid from entering the stomach.

Persons can have one or more type of dysphagia at the same time. Warning signs of dysphagia include:

- Coughing while eating or drinking
- Coughing after the swallow
- Choking, coughing up food particles
- Uncoordinated chewing or swallowing
- Food pocketed between the cheek or gum
- Leakage of food/liquid through the nose
- Drooling/leakage of liquid or food from the mouth
- Slow eating
- Labored or effortful swallowing
- Complaints of pain after or during eating
- Wet cough
- Gurgling voice
- Facial grimacing/reddening of the face
- Eye watering

When one or a combination of warning signs are noted, a consultation for a possible swallowing disorder is immediately warranted. The consultation from a physician or speech-language pathologist will include testing to look at the integrity of the swallowing mechanism. Following testing, recommendations and individualized treatment plans are created to address the specific impairments and to develop efficient and effective treatment. Research has indicated swallowing rehabilitation can be successful in reducing the risk of pneumonia and improving nutritional intake/status (Logeman, p.246). ❖

Written by Angie McCalla, MS, CCC-SLP, CBIS. Copyright January 2005 – Rainbow Rehabilitation Centers, Inc. All rights reserved. Printed in the United States of America. No part of this publication may be reproduced in any manner whatsoever without written permission from Rainbow Rehabilitation Centers, Inc. For information, contact the editor at:

RainbowVisions Magazine
Rainbow Rehabilitation Centers, Inc.
5570 Whittaker Road, Ypsilanti, MI 48197, USA
E-mail: rainbowvisions@rainbowrehab.com

References:

Agency for Health Care Policy and Research (1999 March), United States Department of Health and Human Services. *Diagnosis and treatment of swallowing disorders in acute-care stroke patients.* [AHCPR Pub. No. 99-E023]. Washington, DC. Retrieved from Medscape online database: <http://www.medscape.com>

American Speech Language Hearing Association (2004). *Special Populations: Dysphagia – 2004 edition* [7 paragraphs]. Communication Facts. Available: <http://www.asha.org/members/research/reports/dysphagia.htm>

Duong, T.T., Englander, J., Wright, J., Cifu, D.X., Greenwald, B. D., & Brown, A.W. (2004). *Relationship between strength, balance, and swallowing deficits and outcome after traumatic brain injury: A multicenter analysis.* [On-line]. *Archives of Physical Medicine and Rehabilitation*, 85, 1291-1297. Abstract from: Brain Injury Association of America. Available: http://www.biausa.org/Pages/modelsystems/tbi_ms_76.html

Kelly, J. H. & Buchholz, D.W. (1996, May). *Nutritional management of the patient with a neurologic disorder.* *Ear, Nose & Throat Journal*, 75(5), pp. 293-299.

Logeman, Jerri A., (1998). *Evaluation and Treatment of Swallowing Disorders*, 2nd edition. TX: pro.ed

National Institute on Deafness and Other Communication Disorders (1998 October), National Institutes of Health. *Dysphagia.* [NIH Pub. No. 99-4307]. Washington, DC. Available: <http://www.nidcd.nih.gov/health/voice/dysph.asp>

Spiekler, Michael. (2000, June). *Evaluating Dysphagia* [34 paragraphs]. *American Family Physician*, 61. Available: <http://www.aafp.org/afp/20000615/3639.html>